

Strangulated eventration through optical trocar in the immediate postoperative period after bariatric surgery

Manuel Ferrer-Márquez¹, Manuel García-Redondo¹, Pedro A Sánchez-Fuentes¹, José Ruíz-Pardo¹

¹Servicio de Cirugía General y Digestiva. Hospital Universitario Torrecárdenas, Almería. Spain

E-mail: m.garcia.redondo@outlook.es

DOI: <https://www.doi.org/10.53435/funj.00922>

Received: 13-Januari-2023

Accepted: March-2023

Online Publication: N^o May 2023

Abstract

One of the most underestimated complications of bariatric surgery is the presence of internal hernias at the entry site of working trocars. Evidence from non-bariatric populations supports the approach of closing the fascia in incisions larger than 10 mm, although cases have also been reported even with trocars smaller than 5 mm. However, the fact that these are patients with extensive abdominal wall adipose panniculus, together with the use of blunt optically visible entry trocars, means that few bariatric surgical teams systematically close

such entry holes, with the risk that this may entail. We present the case of a strangulated eventration in the immediate postoperative period following laparoscopic gastric bypass surgery.

Keywords:

- Bariatric surgery
- Eventration
- Gastric bypass
- Incisional hernia

Morbid obesity is currently known as the great epidemic of the 21st century¹, with bariatric surgery being the main treatment when conservative measures fail²⁻⁴. One of the most underestimated complications of bariatric surgery is the presence of internal hernias at the entry site of the working trocars^{5,6}. Evidence from non-bariatric populations supports the approach of closing the fascia in incisions larger than 10 mm, although cases have also been reported even with trocars smaller than 5 mm. However, the fact that these are patients with extensive abdominal wall adipose panniculus, together with the use of optically blunt entry trocars, means that few bariatric surgical teams systematically close such entry holes, with the risk that this may entail.

We present the case of a 59-year-old female patient with a BMI of 53 kg/m² and a personal history of diabetes mellitus, arterial hypertension, and sleep apnoea syndrome. The patient had undergone laparoscopic vertical gastrectomy 24 months earlier. During follow-up, and despite significant weight loss (%EIMCP=62), the patient presented severe gastro-oesophageal reflux with associated persistent emetic syndrome. It was therefore decided to convert to simplified gastric bypass.

The surgery was performed using five 12mm trocars

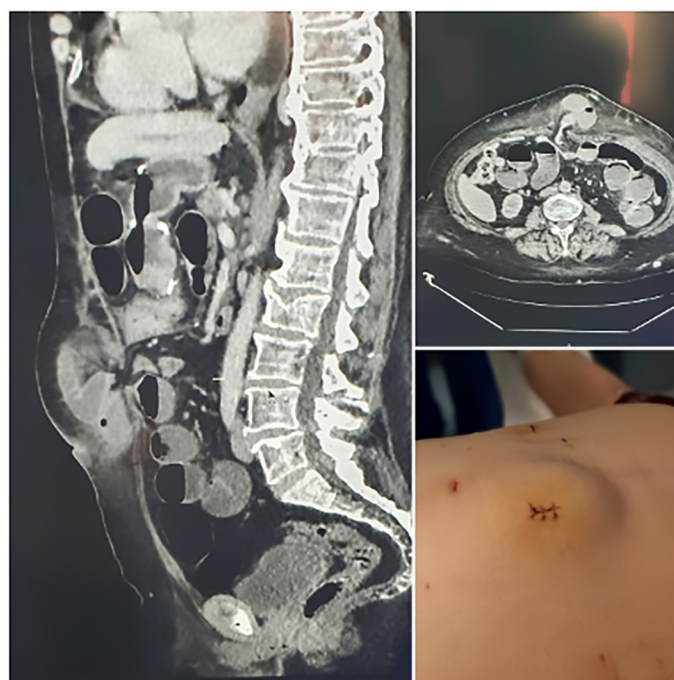


Figura 1: Tumoración supraumbilical e imágenes del TC abdominal evidenciando hernia estrangulada.

without incident, and the patient was discharged 48 hours later. Five days later, the patient came to the emergency department with a tumour in the abdominal wall measuring

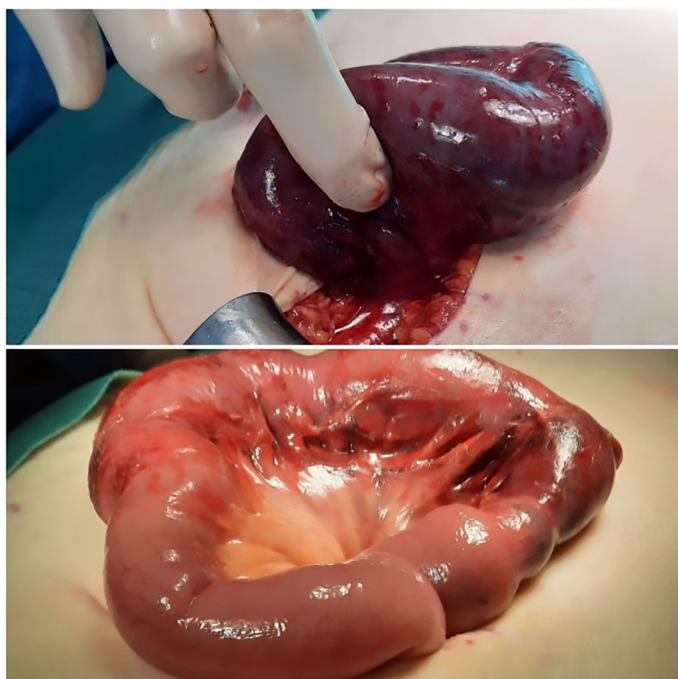


Figura 2: Asas de intestino delgado con signos de isquemia tras liberar la eventración

8 cm in diameter at the level of one of the entry trocars, which was non-reducible and painful on palpation (figure 1). After assessment and an imaging test (abdominal CT scan), a diagnosis was made of strangulated supraumbilical eventration, associated with retrograde dilatation of the small bowel loops. Emergency surgery was performed by enlarging the entry trocar where the incisional hernia was located, revealing a small bowel loop (common loop) with signs of ischaemia that did not recover, requiring its resection (figure 2). After a slow postoperative period, the patient progressed favourably and was discharged from hospital after 6 weeks.

Data from retrospective studies with adequate follow-up intervals indicate a remarkably high prevalence of trocar site hernias after bariatric surgery, ranging from 15-40%^{7,8}. However, in the study by Karampinis et al⁹, the prevalence of abdominal wall defects in patients who received fascial closure was 37% compared to 34% in patients who did not receive fascial closure ($p = 0.37$) (studied by ultrasonography). The only factor that was associated with an increased risk of trocar site hernias in this study was excessive weight loss ($p = 0.05$).

Most studies reporting long-term outcomes after bariatric surgery report several cases of urgent strangulated trocar-

site hernias, although the actual prevalence remains unknown. In contrast to these cases, the one presented by our team appears in the immediate postoperative period, requiring bowel resection.

A systematic review and meta-analysis published in 2019¹⁰ clearly indicates that trocar-site hernias are a vastly underestimated problem in bariatric surgery. They conclude that patients with a higher BMI appear to have a higher risk of developing hernia. The role of fascial closure remains complicated, but closure can be considered when trocars larger than 10 mm are used.

References

1. Gensthaler L, Felsenreich DM, Jedamzik J, Eichelster J, Nixdorf L, Bichler C, et al. Trends of Overweight and Obesity in Male Adolescents: Prevalence, Socioeconomic Status, and Impact on Cardiovascular Risk in a Central European Country. *Obes Surg*. 2022 Apr;32(4):1024-1033
2. Arterburn DE, Telem DA, Kushner RF, Courcoulas AP. Benefits and Risks of Bariatric Surgery in Adults: A Review. *JAMA*. 2020 Sep 1;324(9):879-887
3. Chang SH, Stoll CR, Song J, Varela JE, Eagon CJ, Colditz GA. The effectiveness and risks of bariatric surgery: an updated systematic review and meta-analysis, 2003-2012. *JAMA Surg*. 2014 Mar;149(3):275-87
4. Colquitt JL, Picot J, Loveman E, Clegg AJ. Surgery for obesity. *Cochrane Database Syst Rev*. 2009 Apr 15;(2):CD003641.
5. Pilone V, Di Micco R, Hasani A, Celentano G, Monda A, Vitiello A, et al. Trocar site hernia after bariatric surgery: our experience without fascial closure. *1. Int J Surg*. 2014;12 Suppl 1:S83-6.
6. Swank HA, Mulder IM, la Chapelle CF, Reitsma JB, Lange JF, Bemelman WA. Systematic review of trocar-site hernia. *Br J Surg*. 2012 Mar;99(3):315-23.
7. Ahlqvist S, Bjork D, Weisby L, Israelsson LA, Cengiz Y. Trocar site hernia after gastric bypass. *Surgical technology international* 2017 Jul 25;30:170-174.
8. Rebibo L, Dhahri A, Chivot C, Cyril C, Yzet T, Regimbeau JM. Trocar site hernia after laparoscopic sleeve gastrectomy using a specific open laparoscopy technique. *Surgery for obesity and related diseases : official journal of the American Society for Bariatric Surgery* 2015 Jul-Aug;11(4):791-796.
9. Karampinis I, Lion E, Hetjens S, Vassilev G, Galata C, Reissfelder, et al. Trocar Site HERNIAS After Bariatric

Laparoscopic Surgery (HERBALS): a Prospective Cohort Study.
Obes Surg, 2020 May;30(5):1820-1826.

10. Karampinis I, Lion E, Grilli M, Hetjens S, Weiss C, Vassilev G, et al. Trocar Site Hernias in Bariatric Surgery-an Underestimated Issue: a Qualitative Systematic Review and Meta-Analysis. *Obes Surg. 2019 Mar;29(3):1049-1057.*

©2023 seco-seedo. Published by bmi-journal.
All rights reserved

